

Proposed Guidelines for the Diagnosis of Canine Idiopathic Dilated Cardiomyopathy

The ESVC Taskforce for Canine Dilated Cardiomyopathy

Joanna Dukes-McEwan¹; Michele Borgarelli²; Anna Tidholm³;
Andrea C Vollmar⁴; Jens Häggström⁵

Abstract

Dilated cardiomyopathy (DCM) is a major cause of morbidity and mortality in various dog breeds. The diagnosis of overt DCM is not normally problematic, although the importance of active exclusion of other causes of the dilated, hypokinetic heart is emphasised. Recent interest in human familial DCM has prompted a number of researchers to investigate the genetic basis of canine DCM. Prospective screening of dogs from lines with familial prevalence of DCM may identify dogs with pre-clinical ("occult") DCM. Dogs with other echocardiographic abnormalities or arrhythmias may also be identified. It is clear that dogs, like humans, have a prolonged pre-symptomatic phase of the disease extending over years. The ESVC DCM taskforce was established to provide the veterinary cardiology community with guidelines for the diagnosis of DCM, predominantly based on 2D and M-mode echocardiography. Diagnosis of DCM requires all of the following: (i) Left ventricular dilatation (ii) Reduced systolic function (iii) Increased sphericity of the left ventricle. We propose a scoring system for the identification of dogs in the pre-clinical stages. These include a number of major criteria and minor criteria. Future prospective longitudinal studies are required to test these in different breed populations to assess their predictive power and further refinements may be required. The importance of post mortem confirmation of disease is emphasised, and the two major histopathological features associated with DCM, the attenuated wavy fibre and the fibro-fatty infiltration-degenerative forms, require further investigation to identify the different aetiopathogenetic factors which may be involved.

Key words: Dog, Dilated Cardiomyopathy, Echocardiography, Histopathology, Familial Dilated Cardiomyopathy

Introduction

Cardiomyopathies are defined as diseases of the myocardium associated with cardiac dysfunction¹. The new classification of cardiomyopathies by the World Health Organisation is by dominant pathophysiology or, where possible, by aetiological / pathogenetic factors. Dilated cardiomyopathy is defined as being characterised by dilatation and impaired contraction of the left ventricle or both ventricles¹. The diagnosis of idiopathic dilated cardiomyopathy (DCM) requires the active exclusion of

other cardiac, pulmonary or systemic disease which may secondarily induce a similar phenotype².

Dilated cardiomyopathy is prevalent in certain breeds of dog and is rare in cross breeds. Furthermore, DCM is strongly familial in some breeds, and canine DCM has long suspected to have a genetic basis³. In contrast, it has only been in the last decade that human DCM has been recognised to have a genetic basis in an important subset of about 30% of cases. Various modes of inheritance have been reported, but autosomal dominant transmission is

¹BVMS, MVM, PhD, DVC, MRCVS, Dip.ECVIM-CA (Cardiology), Cardiology Service, Institute of Comparative Medicine, Division of Small Animal Clinical Studies: Dept. Veterinary Clinical Studies, University of Glasgow Veterinary School, Bearsden, Glasgow G61 1QH, Scotland, UK. E-mail: J.Dukes-McEwan@vet.gla.ac.uk

²DVM, Dip.ECVIM-CA (Cardiology): Dipartimento di Patologia Animale, Faculty of Veterinary Medicine, Via Leonardo Da Vinci 44, 10095 Grugliasco, Italy.

³DVM, PhD, Dip.ECVIM-CA (Cardiology): Albano Animal Hospital, Stockholm, Sweden.

⁴DVM, Dip.ECVIM-CA (Cardiology): Small Animal Vet Clinic, Wissen, Germany.

⁵DVM, PhD, Dip.ECVIM-CA (Cardiology): Dept. of Small Animal Medicine and Surgery, Faculty of Veterinary Medicine, Uppsala, Sweden.

most commonly reported for non-syndromic DCM in humans (i.e. not associated with skeletal myopathy or other phenotype), with over thirteen different loci described⁴. In a specific dog breed, which represents a closed population, DCM is fairly uniform and it is probable that a similar genetic aetiology underlies the cause of DCM within a breed. Phenocopies (e.g. ischaemic cardiomyopathy, excessive alcohol consumption, myocarditis) are less common than in human patients. In dogs, an autosomal dominant transmission has been reported in Irish Wolfhounds⁵, Newfoundlands⁶ and Dobermanns⁷. Other modes of transmission have been reported in other breeds^{8,9}.

Epidemiology

Dilated cardiomyopathy has been reported to have an overall prevalence of 0.5%, based on the Veterinary Medical Database at Purdue University for the period 1986 - 1991¹⁰. This only included dogs with clinical signs referable to heart disease, particularly congestive heart failure. Further analysis showed higher prevalence in pedigree dogs (0.65%) compared with cross-breeds (0.16%), and prevalence in certain specific breeds was very high (e.g. Deerhounds 6.0%; Dobermanns, 5.8%, Irish Wolfhounds, 5.6%; great Danes, 3.9%; Boxers, 3.4%; Newfoundlands, 1.3%). Large and giant breed dogs are most predisposed to develop DCM, with the exception of spaniel breeds (especially Cocker Spaniels (English and American)). Prevalence increases with age, and males are usually reported as being over-represented¹⁰ in the population of dogs with congestive heart failure. Prevalence rates are much higher in prospective studies screening for the presence of DCM, when dogs without clinical signs may be detected (e.g. Dobermanns, 63.2%¹¹; Irish Wolfhounds, 24.2%¹²; Newfoundlands, 17.6%¹³). It should, however, be noted that concentration on certain family lines in these studies may over-estimate actual population prevalence. In these prospective studies, there is not usually a marked sex-predisposition reported, although male dogs may show an earlier onset of congestive heart failure¹⁴.

Natural history of the disease

Increasing interest in screening families of dogs where DCM is prevalent has led to an appreciation that there is a very long phase of the disease which is not associated with clinical signs evident to the owner or veterinary surgeon. Indeed, the phase with clinical signs, usually associated with the presence of congestive heart failure, is the final stage of several years of insidious progression. Identification of this pre-clinical phase may be challenging to diagnose and one of the aims of this paper is to provide cardiologists with criteria on which to base a diagnosis.

Dogs which are initially normal gradually progress through these pre-clinical stages to eventually develop congestive failure, or sudden death may intervene at any stage. In dogs with an older age of onset, it is possible that concurrent illness is responsible for their death prior to any recognition of DCM.

Survival

Prediction of survival times and identification of factors influencing mortality in the canine patient with DCM is of interest for dog owners as well as veterinarians. Predictive factors of survival rate in different studies include clinical class of heart failure, presence of pleural effusion and pulmonary oedema, echocardiographic parameters, the presence of ventricular premature complexes (VPCs), and presence of biventricular heart failure and atrial fibrillation (in Doberman Pinschers¹⁵). In one study of 189 dogs with DCM only three of 27 tested variables were shown to influence survival, i.e. young age at presentation, dyspnoea and ascites¹⁶. Another study of 37 dogs of various breeds identified pleural effusion and pulmonary oedema as independent prognostic indicators for dogs with DCM¹⁷. These studies did not find breed (e.g. Dobermanns) or parameters of systolic function to be significant prognostic indicators in canine DCM.

Survival times in different studies are compared in Table 1. Survival rate at one year was exceptionally low in a study of Dobermanns¹⁵, which may indicate that the fatty infiltration - degenerative type of DCM carries a worse prognosis compared with the attenuated wavy fibre type of DCM (see histopathology section). Medical treatment, especially ACE inhibitors and beta-blockers, may influence survival in dogs with congestive heart failure, but this was only evaluated in two of the studies. However, as the administration of ACE inhibitors and beta-blockers varied considerably, this may also be a source of variation of survival times between the studies (Table 1).

Histopathological characteristics of DCM

Gross pathology examination of dogs with DCM generally shows dilatation of either all four cardiac chambers or predominant dilatation of the left chambers. Myocardial eccentric hypertrophy, rather than true dilatation, is evidenced by increased heart weight: body weight ratio, together with a decreased ratio of the left ventricular thickness to chamber diameter²⁴.

An example of histology from the normal canine myocardium is shown in Figure 1A. Some studies on histopathological findings in the myocardium of dogs with the clinical diagnosis of DCM report non-specific findings²⁵. This is consistent with the histopathological findings of human idiopathic DCM, where the degree of fibrosis, degeneration and fibre attenuation may be variable^{26,27}. In dogs, however, two distinct histopathological forms of DCM have been described by various authors:

The attenuated wavy fibre type of DCM has been described by several authors in a total of 119 dogs of many giant-, large- and medium-sized breeds (including some boxers and Dobermanns)^{8,28-33}. The myocardial lesions associated with the attenuated wavy fibre type of DCM consist of myocytes that are thinner than normal (< 6 µm in diameter) with a wavy appearance, comprising at least half of the thickness of the myocardial specimens from the upper

Table 1 - Comparisons between studies of survival in dogs with DCM.

	Monnet <i>et al.</i> 1995 ¹⁷	Tidholm <i>et al.</i> 1997 ¹⁶	Calvert <i>et al.</i> 1997 ¹⁵	Borgarelli <i>et al.</i> 1997 ¹⁸	Ettinger <i>et al.</i> 1998 ¹⁹	The Bench study group 1999 ²⁰	Borgarelli <i>et al.</i> 2000 ²¹	Vollmar 2000 ²²	Martin <i>et al.</i> 2001 ²²	Tidholm <i>et al.</i> 2001 ²³
Number of dogs	37 (12 Dobe)	189 (38 breeds)	66 Dobe	31 (11 Great Danes)	43 (24 Dobe)	37	78	39 (Irish Wolf hounds)	217	19
Functional class of heart failure	I-II [^] : 13 dogs III-IV [^] : 24 dogs	IV [^]	IV [^]	IV [^]	III [^] or IV [^]	II or III*	I-III*	I*: 4 dogs II*: 18 dogs III*: 17 dogs	I*: 25 II*: 97 III*: 95	III*
Median survival time	65 days	27 days	45.5 days	120 days	50 days (placebo) 130 days (enalapril)	250 days (placebo) 100 days (benazepril)	193 days	I*: 390 days II*: 165 days III*: 83 days	140 days	130 days
Survival rate at one year	37.5%	17.5%	3%	44%	-	22% (placebo) 46% (benazepril)	54%	-	20%	21%
Survival rate at two years	28%	7.5%	-	-	-	-	-	-	7%	11%
Percentage of dogs given ACE inhibitors	27%	9%	38%	100%	49%	46%	100%	-	90%	0%
Percentage of dogs given β- blockers	11%	22%	7.6%	0%	0%	0%	0%	-	16%	100%

* ISACHC class, [^]NYHA class, Dobe = Dobermanns

Figure 1A - Histology specimen from the myocardium of a dog which had no evidence of cardiac disease. Haematoxylin & Eosin stain. Size bar = 100 μm.

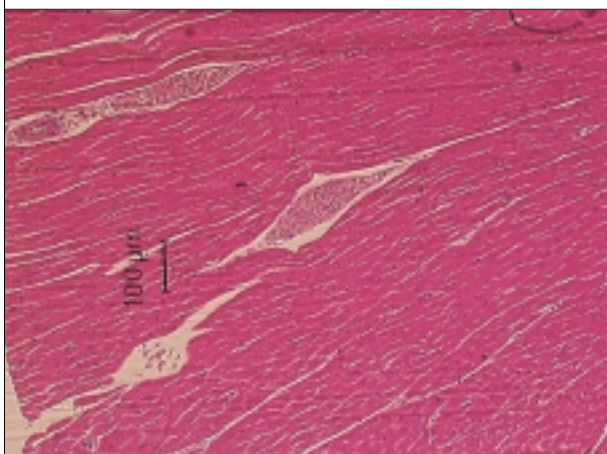


Figure 1B - Histology specimen from the myocardium of a dog with attenuated wavy fibre type of canine idiopathic DCM. The myocytes are thinner than normal and have a wavy appearance. The myocytes are separated by a clear space, indicating oedematous fluid, which is generally free from cellular infiltrates. Haematoxylin & Eosin stain. Size bar = 200 μm.

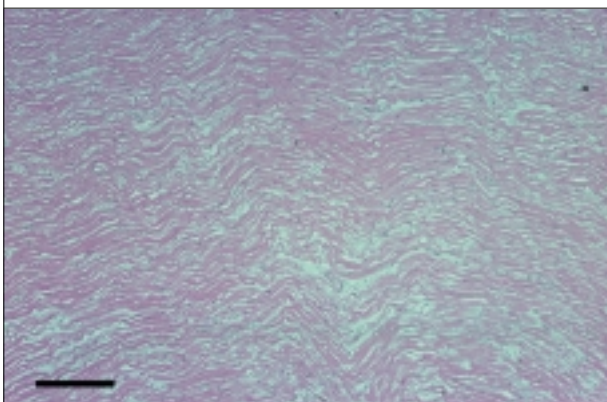
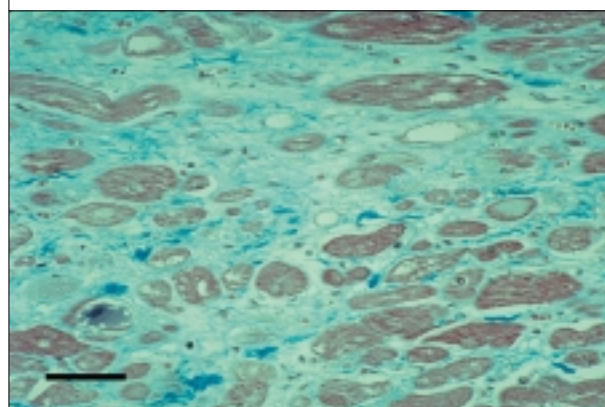


Figure 1C - Histology specimen from the myocardium of a dog with the fatty infiltration- degenerative type of canine idiopathic DCM. Vacuolisation and fragmentation of myocytes as well as prominent proliferation of connective tissue are evident. Trichrome stain. Size bar = 100 μm.



and lower portions of the left ventricular wall. The myocytes are separated by a clear space, indicating oedematous fluid that is generally free from cellular infiltrates (Figure 1B). There may also be diffuse subendocardial fibrosis present. The presence of myocardial lesions associated with the attenuated wavy fibre type of DCM was found to have a very high sensitivity (98%) and specificity (100%) for DCM in a study of 70 dogs with the clinical and echocardiographic diagnosis of DCM, when final diagnosis was made post mortem³⁰. As attenuated wavy fibres were not found in the myocardium of dogs with cardiac dilatation caused by heart disease other than DCM, this myocyte abnormality does not seem to be induced by chronic volume overload and stretching of the myocyte, as has been suggested. Attenuated wavy fibres have been reported as a major histological finding in human DCM, although infrequently^{34,35,36}. Atrophy or attenuation of myofibres without a wavy appearance has also been described^{37,38,39,40}. As attenuated

wavy fibres have been found in the myocardium of dogs prior to any clinical or echocardiographic evidence of disease, it has been proposed that they represent an early DCM lesion³¹.

The fatty infiltration - degenerative type of DCM was first described in 64 Boxers by Harpster⁴¹ in 1983. The presence of myocardial lesions associated with the fatty infiltration - degenerative type of DCM, i.e. the cardiomyopathy of boxers, include myocytolysis, myofibre degeneration, vacuolization and myocyte atrophy with extensive fibrosis and fatty infiltration^{41,42}. The lesions have been compared to isolated right ventricular cardiomyopathy in dogs and in humans. Four different reports on histological examinations of a total of 64 Doberman Pinschers with DCM describe findings similar to the cardiomyopathy of Boxers, i.e. fibrosis, fatty infiltration, myofibre degeneration, myocyte atrophy, and sometimes vacuolization^{43,44,45,46} (Figure 1C). These features resemble those described for arrhythmogenic right ventricular cardiomyopathy in humans, which may affect the entire myocardium in later stages^{47,48}.

Differentiating between histologically different types of DCM may not be of major clinical importance, but is of great scientific importance as it may increase our knowledge concerning the aetiology and the pathogenesis of canine DCM.

Clinical findings in dogs with DCM

The two phases of canine DCM, dichotomised by the presence or absence of clinical signs, should be identified separately.

Pre-clinical DCM

This is the long asymptomatic phase prior to development of clinical signs. It has previously been referred to as occult DCM by some authors⁴⁹. However, the term “occult” implies that it cannot be identified by any clinical test, and so the authors prefer the term “preclinical”.

Overt DCM

This is the phase associated with the presence of clinical signs.

Clinical characteristics of dogs with overt DCM

Clinical signs in dogs with DCM and congestive heart failure (CHF) include breathlessness or dyspnoea, cough, depression, exercise intolerance, inappetence, syncope, weight loss, abdominal distention, and polydipsia. Clinical examination commonly reveals dyspnoea, tachypnoea, rales, crackles and increased breath sounds, tachycardia, arrhythmia, and, in some dogs, a systolic murmur of low to moderate intensity (grade I-III/VI). Further findings may include diastolic gallops or an audible third heart sound (S3), weak femoral arterial pulses, pulse deficit, ascites and distension of the jugular veins, pale mucous membranes, weight loss and muscle wasting and, sometimes, elevation of the body temperature⁵⁰. The clinical presentation may vary from case to case and according to breed.

Laboratory findings in dogs with overt DCM

Evaluation of haematology and blood chemistry is important in dogs with DCM to exclude other primary or concurrent disease. There may be no abnormalities; in the majority of dogs, routine biochemical analysis and haematology are within the reference ranges¹⁶. Laboratory abnormalities may reflect the effects of low cardiac output, congestion, and neurohormonal activation. Increases in blood urea may be detected in some dogs, possibly a sign of prerenal azotaemia due to low cardiac output. Serum concentrations of biochemical markers of myocardial damage, such as Troponin I, may be within the normal reference range or slightly increased in dogs with DCM⁵¹. Thus, significantly increased concentrations in a patient with suspected DCM should raise the suspicion of causes other than DCM, such as myocarditis or myocardial infarction, to explain echocardiographic findings of ventricular hypokinesia and dilatation. Alternatively, myocardial infarction may occur as a complication of DCM. Plasma concentrations of thyroid stimulating hormone (TSH) and total thyroxine (TT4) are within the normal limits in the majority of dogs with DCM⁵². Increased circulating neurohormones have been detected in dogs with DCM, and in the future evaluation of these may become routine^{52,53}.

Electrocardiographic findings in dogs with overt DCM

In general, the electrocardiogram and the presence of ECG abnormalities have limited value in the diagnosis of DCM, but an ECG is essential for the evaluation of arrhythmias. Most dogs with DCM do show abnormalities on ECG recordings, such as the presence of arrhythmias, abnormal amplitude or duration of P wave or the QRS complex indicating chamber enlargement or conduction abnormalities. Atrial fibrillation is the most commonly diagnosed arrhythmia in dogs with DCM. The presence of ventricular premature complexes (VPCs) and ventricular tachycardia is reported in the majority of Boxers and Dobermanns. With the increased use of 24-hour ambulatory ECG (Holter) recordings, the true prevalence of arrhythmias in dogs with DCM may become better established.

Screening by Electrocardiography and Holter monitoring for dogs with Pre-Clinical DCM

In most breeds, the electrocardiogram is neither sensitive nor specific for the identification of dogs destined to develop DCM or those with asymptomatic disease. Electrocardiography has been shown to be useful in certain breeds, notably Boxers^{41,42,54} and Dobermanns^{14,55}. A single ECG trace is not useful, since it corresponds to a small fraction of the dog's rhythm over a 24 hour period, and identification of abnormalities may be entirely fortuitous. Holter monitoring, a 24 hour ECG recording, is required⁵⁶.

Evidence of ventricular arrhythmia precedes echocardiographic evidence of DCM in the Dobermann by some months or even years^{14,15,57}. In Dobermanns, therefore, Holter monitoring is of proven value in the identification of dogs destined to develop DCM and guidelines have been produced for this breed for acceptable number of VPCs over a 24 hour period¹⁴. Similar longitudinal studies of progression from ventricular arrhythmias to more classical DCM are lacking in the Boxer⁵⁴ although this progression has been proposed^{41,42}. Over 50 ventricular premature complexes over 24 hours is likely to be abnormal in any age of Boxer⁵⁴. In the Boxer, the detection of ventricular ectopy precedes the development of clinical signs by 3 - 4 years⁵⁸. There appear to be geographical differences in the presentation of "Boxer cardiomyopathy". In contrast to the presentation with significant ventricular arrhythmias identified in North American Boxers, with minimal chamber dilation or hypokinesis evident on echocardiography⁵⁴, European Boxers present with congestive heart failure and these more classical features of DCM⁵⁹.

Other breeds which frequently show ventricular ectopy in which Holter monitoring may be useful, include Weimaraners and great Danes, but guidelines have not yet been drawn up. In all breeds, it should be recognised that the presence of ventricular ectopy may reflect other potential causes and presence of these must be excluded.

Other electrocardiographic techniques which are being assessed to identify dogs at risk for development of ventricular arrhythmias or dilated cardiomyopathy include assessment of heart rate variability^{60,61,62,63}, the presence of late potentials on signal averaged ECGs^{64,65} and QT dispersion⁶⁶. However, some of these techniques are cumbersome, have still to be shown to have clinical value, and some are not clinically useful.

Radiographic findings in dogs with DCM

Findings on thoracic radiography in dogs with overt DCM include cardiomegaly, often with prominence of the left atrium, venous congestion, various degrees of interstitial or alveolar pulmonary oedema, and sometimes pleural effusion and ascites. These findings are diagnostic for left-sided or biventricular congestive heart failure, but are not

specific for DCM. Radiography in dogs with pre-clinical DCM is frequently unremarkable although left atrial and/or left ventricular enlargement may be identified.

Echocardiographic diagnosis of dogs with DCM

The diagnosis of DCM is based on the identification of myocardial (predominantly but not solely systolic) dysfunction with the active exclusion of other acquired or congenital cardiac disease. Diagnosis of DCM in a predisposed breed once the patient is symptomatic is not problematic, and echocardiography is the most sensitive method of confirming myocardial dysfunction. Diagnosing the presence of myocardial failure and specific chamber dilatation requires 2D and M-mode echocardiography. However, Doppler echocardiography is required to exclude other significant congenital or acquired cardiac disease which results in a similar phenotype. It should be appreciated that the echocardiographic diagnosis of chamber dilatation and myocardial failure is not specific for DCM; there are uncommon instances of ischaemic cardiomyopathy or myocarditis which are not routinely excluded by veterinary cardiologists other than at necropsy. A confirmed diagnosis of DCM should not be made without active exclusion of other causes of the dilated, hypokinetic heart (Table 2).

The authors recommend that full 2D, M-mode and Doppler echocardiography is carried out with the patient lying in lateral recumbency, scanning through the dependent chest wall, without chemical restraint. It is noted that some operators prefer to examine certain giant breed dogs standing, although lateral recumbency is strongly recommended to ensure thorough and repeatable examinations. M-mode measurements should be obtained according to the recommendations of the American Society of Echocardiography⁶⁷. Two-dimensional echocardiography should be carried out according to ACVIM Cardiology Specialty guidelines⁶⁸. Maximal left ventricular (LV) lengths and volumes are usually imaged from right parasternal long-axis views compared with left apical views⁶⁹ and the authors recommend that calculations for left ventricular volumes, ejection fraction and sphericity indices are obtained from whichever view optimises LV length and volume. Five

Table 2 - Exclusion Criteria Prior to Making a Diagnosis of Idiopathic Dilated Cardiomyopathy

Congenital and other acquired heart diseases
Tachyarrhythmias which may result in a tachycardia induced cardiomyopathy
Systemic hypertension
Pericardial diseases (not mild pericardial effusion that may be secondary to heart failure)
Systemic diseases that might affect cardiovascular function (e.g. hypothyroidism)
History of use of drugs known to affect cardiac function (e.g. doxorubicin)
Metabolic deficiency (e.g. taurine, L-carnitine)
Presence of atrial fibrillation with a fractional shortening > 25% (mean of 5 to 10 beats)

Note, these criteria can be simply and practically excluded in the living dog. At post mortem, other criteria should actively excluded, such as myocardial infarction, other coronary vascular disease, myocarditis etc. The authors recommend that, wherever possible, post-mortem examination is carried out.

cardiac cycles should be evaluated to generate mean measurements for each parameter. In atrial fibrillation, 10 cardiac cycles should be measured.

Reference ranges of cardiac chamber dimensions

Echocardiography is used to define abnormal cardiac dimensions based on normal reference values. These data can be used to define both pre-clinical and overt DCM cases. Currently, many of the available reference values are based on a mixture of breeds and body sizes, although the extreme body sizes are often under-represented. Breed specific data are sparse in the literature and breed specific reference ranges are urgently required to obtain the more narrow reference ranges required for M-mode dimensions or two-dimensional echocardiographic derived left ventricular volumes or ejection fraction. Furthermore, prospective studies are required to assess the sensitivity and specificity of deviations from these reference values as predictive criteria for the development of DCM. Linear regression equations and graphs with confidence intervals are required for consultation for specific breeds. The influence of other variables such as age, body condition, gender and heart rate need to be evaluated in specific breeds.

Breed specific echocardiographic data are available for the following breeds: Afghan Hounds⁷⁰, Beagles⁷¹, Boxers⁷², Cavalier King Charles Spaniels⁷³, Cocker Spaniels (English)⁷⁴, Corgi (Pembroke)⁷⁰, Deerhounds⁷⁵, Dobermanns^{45,76}, Golden Retrievers⁷⁰, great Danes^{77,78}, Greyhounds⁷⁹, Irish Wolfhounds⁸⁰, Newfoundlands^{13,77} and Poodles (miniature)⁷⁰. However, it should be realised that serial monitoring to confirm normality was only carried out in a small number of these studies, over a limited time period^{13,77}.

In general, in man, the cut-off for diagnosing left ventricular enlargement is >112% predicted values based on height and age, corresponding to over two standard deviations above reference values^{81,82}. In a specific breed, using a cut-off value exceeding two standard deviations above the mean reference value is rather conservative but may be useful until more specific linear regression equations are generated. In a range of dog breeds, allometric scaling of M-mode variables has been assessed, with LV M-mode dimensions showing a linear relationship with body weight^{13 (83)}. This formula needs to be prospectively evaluated in breeds at risk of developing DCM to assess its predictive value.

Evaluation of left ventricular systolic function

In the veterinary literature, most studies in dogs use fractional shortening as the major indicator of systolic function. In dogs, values of less than 20 to 25% are considered to be abnormally low and to represent systolic dysfunction. However, in the presence of significant mitral regurgitation, fractional shortening may be misleading.

In humans, ejection fraction is quoted as the main parameter assessing systolic function and ejection fractions (calculated on echo from apical views using Simpson's rule in most studies) are said to be abnormal at values ranging from less than 40% to less than 50%. In dogs, the authors consider that an ejection fraction less than 40% is abnormally low.

Note that this is determined from 2D echocardiographic images obtained from a right parasternal long axis four chamber view (Figure 2).

The end-diastolic and end-systolic ventricular volumes can be normalised to body surface area (BSA) to give an end-diastolic volume index and an end-systolic volume index (EDV-I and ESV-I) in units mls / m². The formula to calculate canine BSA from body weight (Wt) in grammes is:

$$BSA (m^2) = 10.1 \times [Wt(\text{grammes})]^{0.667} \times 10^{-4}$$

(Appendix in Kirk's Current Veterinary Therapy. Small Animal Practice. Volume XIII. Ed. J.D. Bonagura. (2000)).

An ESV-I over 80 ml/m² offers unequivocal evidence for systolic dysfunction, although this may be an excessively conservative value, as the normal canine ESV-I has been suggested to be <30 ml/m².

Evaluation of Diastolic Function

To the authors' knowledge, abnormalities in diastolic function do not appear to precede the systolic dysfunction or changes in chamber dimensions in dogs developing DCM. Pulsed wave Doppler of mitral inflow and pulmonary venous flow to assess diastolic function is not, therefore, required as a screening test to identify animals with pre-clinical DCM. In dogs with overt DCM, however, the authors believe that evaluation of diastolic function will be increasingly recognised as being important in determining prognosis. It has been recently shown that human patients with DCM have not only poor systolic function, but also

Figure 2 - Calculation of left ventricular diastolic and systolic volumes and ejection fraction by modified Simpson's rule, using software available on many echocardiographic machines. Long-axis images which optimise LV length and area are recorded (usually the right parasternal long axis view). A diastolic frame is selected (start of QRS complex). The endocardial border is traced, closing across the mitral annulus. The LV length is measured. The LV cavity is divided into a number of discs, and the volume of each of these is summated by Simpson's rule to give diastolic volume (End-diastolic volume, EDV) (Fig. 2A). This method is relatively independent of geometrical assumptions. The same procedure is followed for the subsequent systolic frame (smallest LV chamber, usually following end of T wave). This gives the end-systolic volume (ESV) (Fig. 2B). The Ejection fraction is calculated as: (EDV-ESV)/EDV x 100%.

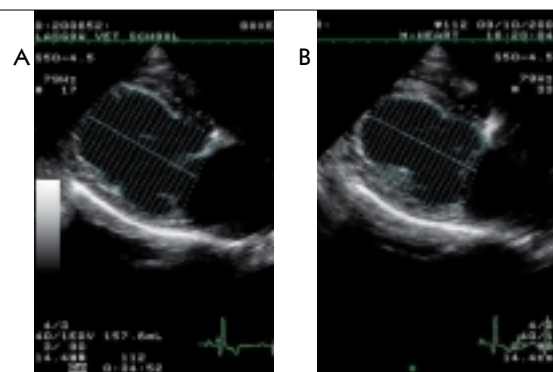
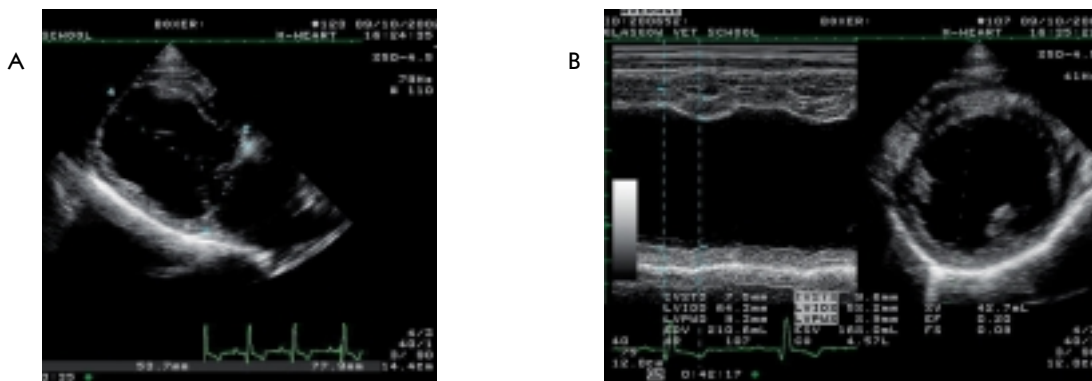


Figure 3 - Determination of the Index of Sphericity, an indication of the degree of rounding of the left ventricle (LV). Long axis four chamber view images which optimise LV length and area are used (usually the right parasternal long axis view). LV length is measured in diastole (start of QRS complex) from LV apex to a line across the mitral annulus (Fig.3A). A mean of 3 – 5 values is recorded. The mean M-mode LV diastolic dimension (Fig. 3B) is used for the LV “width” measurement.

Index of Sphericity = LVlength / LVIDd.

In this example, LV length = 77.9mm, M-mode LVIDd = 64.3mm, so the index is 1.21, indicating marked rounding of the LV due to dilated cardiomyopathy.



abnormal diastolic function. Moreover, it has become increasingly clear that abnormalities of diastolic function play a major role in producing signs and symptoms in human patients presenting with congestive heart failure⁸⁴. Doppler study of trans-mitral flow and pulmonary venous flow has emerged as an increasingly used method for the non-invasive evaluation of diastolic filling patterns in humans⁸⁵. The restrictive filling pattern is the most common pattern in patients with DCM and correlates well with high filling pressure and poor prognosis in people. In particular E wave deceleration time appears a powerful independent predictor of poor prognosis in patients with left ventricular dysfunction, whether symptomatic or asymptomatic, even in patients with atrial fibrillation^{86,87}. Finally, the persistence of the restrictive trans-mitral flow filling pattern despite treatment of heart failure is also associated with a poor prognosis in humans^{88,89}.

Preliminary data from dogs indicated that a restrictive pattern on mitral inflow and a short E wave deceleration time (<80 milliseconds) were significantly associated with a poor prognosis (both parameters, $p < 0.001$)²¹. This study did not find that any of the standard echocardiographic parameters (fractional shortening, mitral EPSS, ESV-I and EDV-I) influenced survival²¹.

Making the Diagnosis of DCM

Other congenital, acquired and systemic conditions must initially be excluded, as listed in Table 2. Because of the high prevalence of DCM and echocardiographic abnormalities, the stringent diagnosis of DCM generally requires all of the following:

1. Left ventricular dilation (especially in systole but also in diastole).

2. Depressed systolic function.

3. Altered geometry of the left ventricle (increased sphericity).

A subjective assessment is often made, but a quantitative method is preferred. The authors propose that a ratio of LV diastolic length (from right parasternal (RPS) long axis four chamber view) to the M-mode LV diastolic dimension (LVIDd) <1.65 represents increased sphericity¹³ (Figure 3). Prospective studies are required to determine the sensitivity and specificity of this figure, and whether it is applicable to all breeds of dog.

In addition, the following features are commonly identified in confirmed overt DCM:

4. Left or bi-atrial enlargement
5. Increased mitral valve M-mode E point to septal separation (EPSS).
6. Arrhythmias recorded on the simultaneous ECG through the echocardiographic examination or during routine ECG or Holter recording are supportive of the presence of DCM. Arrhythmias are more important as a criterion for the diagnosis of DCM in certain breeds, especially ventricular arrhythmias in Dobermanns¹⁴ and Boxers^{41,42,54} and atrial fibrillation in Irish Wolfhounds^{12,90}.

In dogs presenting with congestive heart failure or other manifestations of DCM, it is normally possible to meet these criteria and to make an unequivocal diagnosis (although subsequent post-mortem confirmation is recommended). However, veterinary cardiologists are increasingly being presented with dogs with more equivocal findings, perhaps from breed schemes screening for DCM. Therefore, the authors propose a scoring system which may be of use in

determining whether a particular patient is likely to have pre-clinical DCM or echocardiographic abnormalities which may precede pre-clinical DCM. Such a scoring system may be of use in serial evaluation or longitudinal screening of a population of dogs in ascertaining the presence of progressive disease, as expected in DCM.

A scoring system for the diagnosis of DCM?

It is apparent that in both dogs and humans, echocardiographic abnormalities or the classical echocardiographic findings of DCM may be identified for a considerable time before the patient becomes clinically affected. The identification of such animals poses a problem. Where echocardiography is used as a method of phenotyping in genetic studies of canine DCM, accuracy is essential. One has to be certain that dogs showing these abnormalities have the disease. Advice to breeders on the status of their dog is similarly fraught with difficulties. One solution is to establish a scoring system.

In humans, an arbitrary number of major and minor criteria for the diagnosis of DCM were proposed over a decade ago by Lestuzzi and colleagues⁹¹. The major criteria were based on the LV systolic or diastolic dimensions exceeding 95% confidence intervals of the normal M-mode values (for height and age) and a fractional shortening of less than 26%. Minor criteria included M-mode dimensions exceeding 80% confidence intervals, moderately reduced fractional shortening, enlarged left atrium, and a rounded LV chamber. Using slightly modified criteria, a European collaboration have proposed that the diagnosis of familial dilated cardiomyopathy is fulfilled by either (i) one major criterion or (ii) LV dilatation and one minor criterion or (iii) three minor criteria⁹². Additional minor criteria include the presence of arrhythmias or conduction disturbances and segmental wall motion abnormalities. The active exclusion of other causes of myocardial dysfunction or chamber enlargement is emphasised for a reliable diagnosis. These criteria have been assessed prospectively in investigation of familial DCM in French families⁹³.

We propose that modified criteria will be similarly useful in screening for the canine disease, but these will need to be assessed prospectively. They may require to be modified for specific breeds.

Prior to using these criteria, it is essential that there is active exclusion of other congenital or acquired cardiac diseases and other systemic conditions, which may have secondary effect on the heart. See Table 2.

Proposed major criteria for the diagnosis of canine DCM

1. Left ventricular M-mode systolic or diastolic dimensions exceeding 95% confidence intervals for the individual based on regression equations or predicted reference values, or outside other established breed-specific reference ranges. Account should also be paid to the influence within specific breeds of body surface area, gender or age where these data are available and applicable.
2. Increased sphericity: LV length: M-mode LV diastolic

dimensions is decreased.

The authors propose that a ratio of LV diastolic length (from RPS long axis four chamber view) to the M-mode LV diastolic dimension <1.65 represents increased sphericity¹³.

3.a. EITHER:

M-mode fractional shortening of <20% or 25% (depending on breed-specific reference values).

3.b. AND / OR:

Left ventricular ejection fraction less than 40%.

It is important that breed specific reference ranges are generated or consulted if available. The authors urge particular caution in assessing extreme breeds, or very athletic breeds (which, at rest, often have a low measured fractional shortening).

Proposed minor criteria for the diagnosis of canine DCM

1. The presence of an arrhythmia in a specific breed where the arrhythmia has been shown to be strongly associated with DCM (e.g. increased (for age) ventricular ectopy in Dobermanns or Boxers). Other (cardiac or systemic) causes for ventricular ectopy should be actively excluded.
2. Atrial fibrillation.
3. Increased mitral valve M-mode E point to septal separation (EPSS).
4. PEP:ET ratio increased over 95% confidence intervals (e.g. over 0.4)
5. M-mode fractional shortening in equivocal range (depending on breed-specific references).
6. Left or bi-atrial enlargement

It must be emphasised that other cardiac or systemic disease, including systemic hypertension, must be excluded as far as possible before a firm diagnosis of DCM may be made. The presence of persistent tachyarrhythmias, such as atrial fibrillation, which may result in myocardial failure, must also be considered. They may be the cause or the consequence of myocardial dysfunction and careful consideration of their presence is required prior to making a diagnosis of DCM.

If major criteria score 3 points and minor criteria score 1 point each, a total score of SIX or more should identify dogs with DCM but this must be assessed for various breeds prospectively. Further refinements with number loading of some criteria are possible in certain breeds.

The authors emphasise that the identification of one or more of these major or minor criteria should prompt the cardiologist to serially examine that animal for evidence of progression, which should be identified over some years if DCM is genuinely present. The score should increase over time. Prospective evaluation of screened dogs is recommended by a number of centres to evaluate the usefulness of our proposed criteria in screening for DCM. At this stage, these criteria should be assessed for the diagnosis of DCM, and should not be interpreted as being breeding guidelines.

The genetic basis of DCM: the reason for screening

Canine DCM has long been suspected to be an inherited disease and therefore to have a genetic basis, because of its prevalence in pedigree dog breeds, and in specific families within these breeds¹⁰. In most breeds, an autosomal dominant mode of transmission is reported, despite the inbred nature of most canine pedigrees predisposing them to recessive conditions. This includes DCM in Irish wolfhounds⁵, Dobermanns⁷ and Newfoundlands¹³ and ventricular arrhythmias of Boxers⁵⁴. A well documented autosomal recessive transmission, with identification of a single founder, has been reported for Portuguese water dogs with a juvenile DCM^{8,94}. An X-linked transmission has been proposed for great Danes⁹, although it should be noted that this study may include ascertainment bias, since siblings and litters were not prospectively screened. In Dobermanns, while the disease is recognised to be strongly familial, the actual mode of inheritance has proved difficult to elucidate for many of these families⁹⁵ and may be recessive in others⁹⁶.

In man, over 30% cases of DCM are now appreciated to have a genetic basis (for reviews, see Refs 4 and 97). Some syndromic forms (with skeletal myopathy) are associated with X-linked inheritance, with known mutations in three genes. However, most non-syndromic familial forms of DCM in humans are associated with an autosomal dominant transmission. Over eleven different chromosome loci have been associated with the disease in some families by genetic linkage analysis, although the corresponding gene defect has only been identified for a few of these. A number of other genes have been implicated in some small families, using non-positional candidate gene screening strategies. The proteins encoded by these genes comprise components of the cytoskeleton or the sarcomere attachment to the cytoskeleton. It appears that DCM is likely to be due to cytoskeletal abnormalities⁹⁸, which is consistent with the final phenotype (and the histological findings of attenuated wavy fibres).

Screening candidate genes implicated in dilated cardiomyopathy is underway in a number of dog breeds (e.g. excluded genes include the cardiac actin and desmin genes in Dobermanns^{96,99}, candidate genes for arrhythmogenic right ventricular cardiomyopathy in boxers⁹⁶ and the α -sarcoglycan gene in Dobermanns¹⁰⁰). A genome-wide linkage analysis is in progress in an informative Newfoundland family¹⁰¹.

There is increasing interest among veterinary cardiologists to investigate the genetic basis of DCM in specific breeds, particularly as canine families offer advantages over human families in the further elucidation of genetic causes (larger families, fast generation time, access to three or more generations at a time, more rapid evolution of disease). Prospective, longitudinal screening studies of this type require a stringent diagnosis of affectation and normality. We propose that the scoring system and stringent criteria of the diagnosis suggested here should facilitate such studies.

Discussion

The authors have sought to develop some guidelines and diagnostic criteria for the diagnosis of DCM for use in screening programmes requested or initiated by some breed societies. These have been tested over a limited time in the authors' own practices, but we welcome critical review from colleagues so the guidelines may be refined or adapted for different, specific breeds.

It must be emphasised that DCM is a diagnosis of exclusion and other causes for the dilated, hypokinetic heart should be actively ruled out, and post mortem confirmation of the diagnosis obtained whenever possible.

Atrial fibrillation: an indicator of incipient myocardial disease or causal in the development of systolic dysfunction?

Further controversies are also introduced in this asymptomatic period. For example, dogs may be identified with atrial fibrillation without any significant echocardiographic changes. Atrial fibrillation may be an early indicator of the presence of myocardial disease, and the typical echocardiographic appearance of DCM later develops. This has been suggested in Irish Wolfhounds⁹⁰. It is possible that underlying myocardial disease is responsible for the atrial fibrillation, such as focal atrial cardiomyopathy or myocarditis recognised on atrial endomyocardial biopsy samples in people with recurrent paroxysmal lone AF¹⁰². Conversely, lone atrial fibrillation may result in secondary systolic dysfunction and chamber dilatation due to tachycardia induced cardiomyopathy (in a similar manner to pacing induced models of dilated cardiomyopathy). True lone AF in humans is not associated with any specific chamber enlargement or abnormalities in systolic and diastolic function¹⁰³. However, patients with atrial fibrillation and systolic dysfunction, or those initially considered to have dilated cardiomyopathy, may show significant improvement in systolic function and diminution of chamber dilatation, with conversion to sinus rhythm or appropriate rate control^{104,105,106}. In dogs also, a similar possibility exists; since tachyarrhythmias may also result in a dilated, hypokinetic heart, similar to paced models for DCM, is this atrial fibrillation the cause of myocardial failure, or is it an early marker of incipient disease? In our proposal for criteria for the diagnosis of DCM by a scoring system, in recognition of this controversy, we suggested that the presence of atrial fibrillation is only a minor criterion. This is despite the strong association of atrial fibrillation and dilated cardiomyopathy in breeds such as the Irish Wolfhound^{12,90}. We recommend that in dogs with atrial fibrillation and systolic dysfunction, systolic function should be re-evaluated once the ventricular rate has been normalised (e.g. with medical therapy), before a presumptive diagnosis of DCM is made. Until recently in humans with atrial fibrillation, restoration of sinus rhythm has been seen as a major goal¹⁰⁶ and more emphasis on rhythm control has been urged in the dog¹⁰⁷. However, two large human studies, comparing rate control with rhythm control in patients with atrial fibrillation, show that controlling the ventricular response to atrial fibrillation is far from inferior and may be associated with fewer pharmacological side effects^{108,109}.

Histological classification of DCM

The histological classification into two major types of DCM is attractive, since it is consistent with two major aetiopathogenetic factors¹⁰. However, this histopathological classification has still to be widely accepted by veterinary cardiac pathologists.

Presumably, different specific histological myocardial changes may reflect different disease processes in the myocardium, which may become elucidated by further studies on canine DCM. As the very structure of the myocytes is distorted in the attenuated wavy fibre type of DCM, the cause may be a defect in the cytoskeletal proteins. Mutations in genes encoding for cytoskeletal proteins have been implicated in dilated cardiomyopathy in humans and experimental models⁹⁸. The lack of abnormalities found in the actin gene in Doberman Pinschers⁹⁹, presumably affected with the fatty infiltration - degenerative type of DCM, does not preclude its involvement in the pathogenesis of the attenuated wavy fibre type of DCM, as such involvement has been shown in a small number of human patients with DCM¹¹¹.

It is important that dogs suspected from clinical and echocardiography/ Doppler examinations to have dilated cardiomyopathy should undergo post-mortem examination for a definitive diagnosis, particularly for dogs from families in genetic studies. Other conditions, such as myocardial infarct, severe arterio- or athero-sclerosis, post-myocarditis lesions may mimic dilated cardiomyopathy. Furthermore, mitral valve endocardiosis in large breed dogs is commonly associated with myocardial failure in the late stages. Categorization of dogs into one of the two histopathological classes of DCM, if applicable, will facilitate prospective studies into aetiopathogenesis of this condition.

Echocardiographic abnormalities may precede unequivocal DCM

In both human and dog families, from various breeds, with prospective screening for the presence of familial DCM, it is common to identify minor echocardiographic abnormalities in relatives. Baig and colleagues⁸² divided these into “left ventricular enlargement” and “depressed fractional shortening” categories. Human relatives with left ventricular enlargement (with initially apparently normal systolic function) do progress to develop DCM and furthermore, show other abnormalities including histopathological changes¹¹² and cardiovascular exercise variables¹¹³. Much less investigation of the “depressed fractional shortening” relatives has been published, and they were initially dismissed as a limited manifestation of DCM⁸². In dogs, similar abnormalities are noted in various breeds. In Newfoundlands, the depressed fractional shortening category is most common, with slow progression (over several years) documented in some individuals to eventually develop other criteria for the diagnosis of DCM. The left ventricular enlargement Newfoundlands progress more rapidly (usually within two years). Although fractional shortening and ejection fraction is normal in this latter group, the PEP:ET ratio is increased compared with normal dogs, showing that this may be a more specific predictor of

systolic dysfunction¹³. In view of this progression, the identification of echo abnormalities may be assigned a score, which, with other clinical or electrocardiographic abnormalities, may be used in prospectively screening dogs from families suffering from DCM, to identify individuals which require serial monitoring.

In our proposed scoring system designed to identify animals which should be serially monitored in longitudinal studies, to assess their prognostic significance in the identification of animals destined to develop DCM, we have deliberately identified rigorous criteria to avoid healthy dogs from being falsely identified as having DCM. Although these conservative criteria may fail to identify early asymptomatic DCM cases as being genuinely affected, the presence of a score should prompt serial evaluation of such animals, which should eventually progress to score six or more points to enable an unequivocal diagnosis of DCM.

Genetics

It is clear that studying the genetics of canine DCM should advance the understanding of human DCM. In man, there are many possible phenocopies (ischaemic cardiomyopathy, myocarditis, alcoholism etc.) which confound genetic analyses, whereas these are much more rare in canine families. Just as there have been a large number of loci and genes implicated in human DCM, it is probable that specific breeds will have different mutations in different genes although the recent evolution of dog breeds supports the likelihood that a single mutation is likely to be responsible for the disease within a given breed. In studying the genetic basis of DCM, a robust diagnosis is essential, and it is hoped that the guidelines provided here will facilitate such studies.

Conclusions

The breed differences in DCM, both in manifestations and clinical course, make it unlikely that identical criteria apply to all breeds. However, our scoring system and these criteria offer veterinary cardiologists a starting point for future studies. The criteria and the scoring system may be refined for specific breeds. It is probable that certain criteria will be weighted differently in certain breeds (e.g. ventricular arrhythmias in Dobermanns and Boxers may represent a major criterion). Furthermore, these criteria will provide a minimum data base aimed at increasing our knowledge about the natural history of the development of DCM in specific breeds, and identifying dogs which should be serially monitored. Longitudinal studies are required in specific breeds to prospectively determine the value of these proposals.

References

1. Richardson P, McKenna W, Bristow M, et al. Report of the 1995 World Health Organisation/ International Society and Federation of Cardiology Task Force on the definition and classification of cardiomyopathies. *Circulation* 1996; 93: 841-842.

2. Cobb MA. Idiopathic dilated cardiomyopathy: advances in aetiology, pathogenesis and management. *J Small Anim Pract* 1992; 33: 113-118.
3. Bond B, Tilley LP. Cardiomyopathy in the dog and cat. In Kirk RW ed. *Current Veterinary Therapy. Small Animal Practice Vol VII*. Philadelphia, WB Saunders; 1980: 307-315.
4. Schönberger J, Seidman CE. Many roads lead to a broken heart: the genetics of dilated cardiomyopathy. *Am J Hum Genet* 2001; 69: 249-260.
5. Cobb MA, Brownlie SE, Pidduck HG, Batt RM. Evidence for genetic involvement in dilated cardiomyopathy in the Irish Wolfhound. *Proceedings of the BSAVA Congress 1996*: 215.
6. Dukes-McEwan J. Familial dilated cardiomyopathy (DCM) in Newfoundland dogs. *Proceedings of the 8th ESVIM congress 1998*: 84.
7. Meurs KM. Insights into the heritability of canine cardiomyopathy. *Vet Clin North Am Small Anim Pract* 1998; 28: 1449-1457.
8. Dambach DM, Lannon A, Sleeper MM, Buchanan J. Familial dilated cardiomyopathy of young Portuguese water dogs. *J Vet Intern Med* 1999; 13: 65-71.
9. Meurs KM, Miller MW, Wright NA. Clinical features of dilated cardiomyopathy in great Danes and results of a pedigree analysis: 17 cases (1990-2000). *J Am Vet Med Assoc* 2001; 218: 729-732.
10. Sisson DD, Thomas WP. Myocardial diseases. In Ettinger SJ, Feldman EC ed. *Textbook of Veterinary Internal Medicine, 4th edition*. Philadelphia, WB Saunders; 1995: 995-1032.
11. O'Grady MR, Horne R. The prevalence of dilated cardiomyopathy in Doberman pinschers: a 4.5 year follow-up. *Proceedings of the 16th ACVIM Forum 1998*: 689.
12. Vollmar AC. The prevalence of cardiomyopathy in the Irish wolfhound: a clinical study of 500 dogs. *J Am Anim Hosp Assoc* 2000; 36: 125-132.
13. Dukes-McEwan J. Echocardiographic / Doppler criteria of normality, the findings in cardiac disease and the genetics of familial dilated cardiomyopathy in Newfoundland dogs. PhD thesis. University of Edinburgh. 1999.
14. Calvert CA. Diagnosis and management of ventricular tachyarrhythmias in Doberman Pinschers with cardiomyopathy. In Bonagura JD ed. *Kirk's Current Veterinary Therapy. Small Animal Practice XII*. Philadelphia, WB Saunders; 1995: 799-806.
15. Calvert CA, Pickus CW, Jacobs GJ, Brown J. Signalment, survival and prognostic factors in Doberman pinschers with end-stage cardiomyopathy. *J Vet Intern Med* 1997; 11: 323-326.
16. Tidholm A, Svensson H, Sylvén C. Survival and prognostic factors in 189 dogs with dilated cardiomyopathy. *J Am Anim Hosp Assoc* 1997; 33: 364-368.
17. Monnet E, Orton CE, Salman M, Boon J. Idiopathic dilated cardiomyopathy in dogs: survival and prognostic indicators. *J Vet Intern Med* 1995; 9: 12-17.
18. Borgarelli M, Tarducci A, Bussadori C, et al. Echocardiographic and echo-Doppler prognostic indicators in dogs with dilated cardiomyopathy. *Proceedings of the 7th ESVIM Congress 1997*: 25-28.
19. Ettinger S, Benitz AM, Ericsson GF, et al. Effects of enalapril maleate on survival of dogs with naturally occurring acquired heart failure. *J Am Vet Med Assoc* 1998; 213: 1573-1577.
20. The BENCH (Benazepril in canine heart disease) study group. The effect of benazepril on survival times and clinical signs of dogs with congestive heart failure: Results of a multicentre, double-blinded, placebo-controlled, long-term clinical trial. *J Vet Cardiol* 1999; 1: 7-17.
21. Borgarelli M, Tarducci A, Santilli RA, et al. Echo Prognostic Indicators for DCM. *Proceedings of the 18th ACVIM Forum 2000*: 78-80.
22. Martin M, Celona B, King J, Strehlau, G. A retrospective review of the clinical presentation and survival of 202 cases of canine dilated cardiomyopathy. *Proceedings of the 11th ESVIM congress 2001*: 99-100.
23. Tidholm A, Svensson H, Sylvén C. Effects on survival of combination treatment with propranolol and thyroid hormone or placebo in conjunction with digoxin and frusemide in euthyroid dogs with myocardial hypokinesia and congestive heart failure. *Proceedings of the 11th ESVIM congress 2001*: 159.
24. Tidholm A., Jönsson L. A retrospective study of canine dilated cardiomyopathy (189 cases). *J Am Anim Hosp Assoc* 1997; 33: 544-550.
25. Darke PGG, Else RW. Canine cardiomyopathy. *Vet Annual* 1984; 24: 237-249.
26. Silver MM, Silver MD. Cardiomyopathies. In Silver MD ed. *Cardiovascular Pathology, Volume 1, 2nd edition*. New York, Churchill Livingstone; 1991: 749-765.
27. Wynne J, Braunwald E. Pathology of Dilated Cardiomyopathy. The Cardiomyopathies and Myocarditides. In Braunwald E, Zipes DP, Libby P ed. *Heart Disease. A Textbook of Cardiovascular Medicine, 6th edition*. Philadelphia, WB Saunders; 2001: 1755.
28. Tilley LP, Liu SK. Cardiomyopathy in the dog. *Recent Adv Stud Cardiac Struct Metab* 1975; 10: 641-653.
29. Sandusky GE, Capen CC, Kerr KM. Histological and ultrastructural evaluation of cardiac lesions in idiopathic cardiomyopathy in dogs. *Can J Comp Med* 1984; 48: 81-86.
30. Tidholm A, Häggström J, Jönsson L. Prevalence of attenuated wavy fibres in the myocardium of dogs with dilated cardiomyopathy. *J Am Vet Med Assoc* 1998; 212: 1732-1734.
31. Tidholm A, Häggström J, Jönsson L. Detection of attenuated wavy fibres in the myocardium of Newfoundlands without clinical or echocardiographic evidence of heart disease. *Am J Vet Res* 2000; 61: 238-241.
32. Vollmar AC, Fox PR, Meurs KM, Liu SK. Dilated cardiomyopathy in juvenile Doberman pinscher dogs. *J Vet Cardiol* 2003; 5: 23-27.
33. Sleeper MM, Henthorn PS, Vijayarathay C, et al. Dilated cardiomyopathy in juvenile Portuguese water dogs. *J Vet Intern Med* 2002; 16: 52-62.
34. Davies MJ. The cardiomyopathies: a review of terminology, pathology and pathogenesis. *Histopathology* 1984; 8: 363-393.
35. Scheinin S, Capek P, Radovancevic B, et al. The effect of prolonged left ventricular support on myocardial histopathology in patients with end-stage cardiomyopathy. *Asiao J* 1992; 38: M271-274.
36. McCarthy PM, Nakatani S, Vargo R, et al. Structural and left ventricular histologic changes after implantable LVAD insertion. *Ann Thorac Surg* 1995; 59: 609-613.
37. Olsen EGJ. Pathology of primary cardiomyopathies. *Postgrad Med J* 1972; 48 : 732-737.
38. Edwards WD. Cardiomyopathies. *Hum Pathol* 1987; 18 : 625-628.
39. Olsen EGJ. The pathogenesis of dilated cardiomyopathy. *Postgrad Med* 1992; 68: S7-10.
40. Roberts WC, Ferrans VJ, Buja LM. Pathologic aspects of idiopathic cardiomyopathies. *Comp Pathol Heart* 1974; 13: 349-367.
41. Harpster NK. Boxer cardiomyopathy. In Kirk RW ed. *Current Veterinary Therapy. Small Animal Practice VIII*. Philadelphia, WB Saunders; 1983: 329-337.

42. Harpster NK. Boxer cardiomyopathy: a review of the long term benefits of antiarrhythmic therapy. In Hamlin RL ed. Efficacy of Cardiac Therapy. *Vet Clin North Am Small Anim Pract* 1991; 21: 989-1009.
43. Calvert CA, Chapman WL, Toal RL. Congestive cardiomyopathy in Doberman Pinscher dogs. *J Am Vet Med Assoc* 1982; 181: 598-602.
44. Hazlett MJ, Maxie MG, Allen DG, Wilcock BP. A retrospective study of heart disease in Doberman pinscher dogs. *Can Vet J* 1983; 24: 205-210.
45. Calvert CA, Hall G, Jacobs G, Pickus, C. Clinical and pathologic findings in Doberman Pinschers with occult cardiomyopathy that died suddenly or developed congestive heart failure: 54 cases (1984-1991). *J Am Vet Med Assoc* 1997; 210: 505-511.
46. Everett RM, McGann J, Wimberly HC, Althoff J. Dilated cardiomyopathy of Doberman pinschers: retrospective histomorphologic evaluation on heart from 32 cases. *Vet Pathol* 1999; 36: 221-227.
47. d'Amati G, di Gioia CR, Giordano C, Gallo P. Myocyte transdifferentiation: A possible pathogenic mechanism for arrhythmogenic right ventricular cardiomyopathy. *Arch Pathol Lab Med* 2000; 124 : 287-290.
48. Thiene G, Nava A, Corrado D. Right ventricular cardiomyopathy and sudden death in young people. *N Engl J Med* 1988; 318; 129-133.
49. Calvert CA, Pickus CW, Jacobs GJ. Unfavourable influence of anaesthesia and surgery on Doberman pinschers with occult cardiomyopathy. *J Am Anim Hosp Assoc* 1996; 32: 57-62.
50. Tidholm A, Jönsson L. Dilated cardiomyopathy in the Newfoundland: a study of 37 cases (1983-1994). *J Am Anim Hosp Assoc* 1996; 32: 465-470.
51. Pellander L, Häggström J, Jones B. Troponin I-a possible marker for myocardial damage. *Swed Vet J* 2001; 10: 497-503.
52. Tidholm A, Häggström J, Hansson K. Effects of dilated cardiomyopathy on the renin-angiotensin-aldosterone system, atrial natriuretic peptide and thyroid hormone concentrations in dogs. *Am J Vet Res* 2001; 62: 961-967.
53. Borgarelli M, Tarducci A, Tidholm A, Häggström J. Canine idiopathic dilated cardiomyopathy. Part II: Pathophysiology and therapy. *Vet J* 2001; 162: 182-195.
54. Meurs KM, Spier AW, Miller MW, et al. Familial ventricular arrhythmias in Boxers. *J Vet Intern Med* 1999; 13: 437-439.
55. Calvert CA, Wall M. Results of ambulatory electrocardiography in overtly healthy Doberman pinschers with equivocal echocardiographic evidence of dilated cardiomyopathy. *J Am Vet Med Assoc* 2001; 219: 782-784.
56. Meurs KM, Spier AW, Wright NA, Hamlin RL. Comparison of in-hospital versus 24-hour ambulatory electrocardiography for detection of ventricular premature complexes in mature Boxers. *J Am Vet Med Assoc* 2001; 218: 222-224.
57. Calvert CA, Jacobs GJ, Smith DD, et al. Association between results of ambulatory electrocardiography and development of cardiomyopathy during long-term follow-up of Doberman pinschers. *J Am Vet Med Assoc* 2000; 216: 34-39.
58. Goodwin JK. Holter monitoring and cardiac event recording. *Vet Clin North Am Small Anim Pract* 1998; 28: 1391-1407.
59. Wotton PR. Dilated cardiomyopathy (DCM) in closely related boxer dogs and its possible resemblance to arrhythmogenic right ventricular cardiomyopathy (ARVC) in humans. *Proceedings of the 17th ACVIM Forum* 1999: 88-89.
60. Minors SL, O'Grady MR. Heart rate variability in the dog: is it too variable? *Can J Vet Res* 1997; 61: 134-144.
61. Calvert CA, Jacobs GJ. Heart rate variability in Doberman Pinschers with and without echocardiographic evidence of dilated cardiomyopathy. *Am J Vet Res* 2000; 61: 506-511.
62. Calvert CA, Wall M. Correlations among time and frequency measures of heart rate variability recorded by use of a Holter monitor in overtly healthy Doberman pinschers with and without echocardiographic evidence of dilated cardiomyopathy. *Am J Vet Res* 2001; 62: 1787-1792.
63. Calvert CA, Wall M. Effect of severity of myocardial failure on heart rate variability in Doberman pinschers with and without echocardiographic evidence of dilated cardiomyopathy. *J Am Vet Med Assoc* 2001; 219: 1084-1088.
64. Calvert CA, Jacobs GJ, Kraus M., Brown J. Signal averaged electrocardiography in normal Doberman pinschers. *J Vet Intern Med* 1998; 12: 355-364.
65. Calvert CA, Jacobs GJ, Kraus M. Possible ventricular late potentials in Doberman pinschers with occult cardiomyopathy. *J Am Vet Med Assoc* 1998; 213: 235-239.
66. Spier AW, Meurs KM, Muir WW, et al. Correlation of QT dispersion with indices used to evaluate the severity of familial ventricular arrhythmias in Boxers. *Am J Vet Res* 2001; 62: 1481-1485.
67. Sahn DJ, DeMaria AN, Kisslo JA, Weyman AE. Recommendations regarding quantitation in M-mode echocardiography. *Am J Cardiol* 1978; 58: 1072-1083.
68. Thomas WP, Gaber CE, Jacobs GJ, et al. Recommendations for standards in transthoracic two-dimensional echocardiography in the dog and cat. *J Vet Intern Med* 1993; 7: 247-252.
69. Dukes-McEwan J. Comparison between right and left cardiac windows to determine left ventricular volumes and ejection fraction in six dog breeds with differing somatotypes. *BMUS Proceedings. Eur J Ultrasound* 2002; 27: Supplement 1: S4-S5.
70. Morrison SA, Moise NS, Scarlett J, et al. Effect of breed and body weight on echocardiographic values in four breeds of dogs of differing somatotype. *J Vet Intern Med* 1992; 6: 220-224.
71. Crippa L, Ferro E, Melloni E, et al. Echocardiographic parameters and indices in the normal Beagle dog. *Lab Anim* 1992; 26: 190-195.
72. Herrtage ME. Echocardiographic measurements in the normal Boxer. *Proceedings of the 4th ESVIM Congress* 1994: 172-173.
73. Häggström J, Hansson K, Kvart C, et al. Secretion patterns of the natriuretic peptides in naturally acquired mitral regurgitation attributable to chronic valvular disease in dogs. *J Vet Cardiol* 2000; 2: 7-16.
74. Gooding JP, Robinson WF, Mews GC. Echocardiographic assessment of left ventricular dimensions in clinically normal English cocker spaniels. *Am J Vet Res* 1986; 47: 296-300.
75. Vollmar AC. Kardiologische Untersuchungen beim Deerhound, Referenzwerte für die Echodiagnostik. *Kleintierpraxis* 1998; 43: 497-508.
76. O'Grady MR, Horne R. Occult dilated cardiomyopathy in the Doberman pinscher. *Proceedings of the 13th ACVIM Forum* 1995: 298-299.
77. Koch J, Pedersen HD, Jensen AL, Flagstad A. M-mode echocardiographic diagnosis of dilated cardiomyopathy in giant breed dogs. *J Vet Med* 1996; 43: 297-304.
78. Tarducci A, Borgarelli M, Bussadori C, et al. Valori ecocardiografica negli alani normali. (Echocardiographic parameters in normal great Danes). *Atti Soc Ital Sci Vet* 1997; 17: 593-594.

79. Page A, Edmunds G, Atwell RB. Echocardiographic values in the greyhound. *Aust Vet J* 1993; 70: 279-283.
80. Vollmar AC. Use of echocardiography in the diagnosis of dilated cardiomyopathy in Irish wolfhounds. *J Am Anim Hosp Assoc* 1999; 35: 279-283.
81. Keeling PJ, Gang Y, Smith G, et al. Familial dilated cardiomyopathy in the United Kingdom. *Br Heart J* 1995; 73: 417-421.
82. Baig MK, Goldman JH, Caforio ALP, et al. Familial dilated cardiomyopathy: cardiac abnormalities are common in asymptomatic relatives and may represent early disease. *J Am Coll Cardiol* 1998; 31: 195-201.
83. Cornell CC, Kittleson MD, Della Torre P, et al. Allometric scaling of M-mode variables in normal adult dogs. *Proceedings of the 11th ESVIM Congress* 2001: 102-103.
84. Nishimura RA, Tajik JA. Evaluation of diastolic filling of left ventricle in health and disease: Doppler echocardiography is the clinician's Rosetta Stone. *J Am Coll Cardiol* 1997; 30: 8-18.
85. Chen L, Benjamin EJ, Larson MG, et al. Doppler diastolic filling indexes in relation to disease states. *Am Heart J* 1996; 131: 519-524.
86. Giannuzzi P, Temporelli PL, Bosimini E, et al. Independent and incremental prognostic value of Doppler-derived mitral deceleration time of early filling in both symptomatic and asymptomatic patients with left ventricular dysfunction. *J Am Coll Cardiol* 1996; 28: 383-390.
87. Temporelli PL, Scapellato F, Corra U, et al. Estimation of pulmonary wedge pressure by transmitral Doppler in patients with chronic heart failure and atrial fibrillation. *Am J Cardiol* 1999; 83: 724-727.
88. Pinamonti B, Di Lenarda A, Sinagra G, Camerini F. Restrictive left ventricular filling pattern in dilated cardiomyopathy assessed by Doppler echocardiography: clinical, echocardiographic and hemodynamic correlations and prognostic implications. *Heart Muscle Disease Study Group. J Am Coll Cardiol* 1993; 22: 808-815.
89. Pinamonti B, Zecchin M, Di Lenarda A, et al. Persistence of restrictive left ventricular filling pattern in dilated cardiomyopathy: an ominous prognostic sign. *J Am Coll Cardiol* 1997; 29: 604-612.
90. Brownlie SE, Cobb MA. Observations on the development of congestive heart failure in Irish wolfhounds with dilated cardiomyopathy. *J Small Anim Pract* 1999; 40: 371-377.
91. Lestuzzi C, Nicolosi GL, Neri A, et al. Familial dilated cardiomyopathy: a transverse and longitudinal clinical and echocardiographic study. *Int J Cardiol* 1991; 33: 225-232.
92. Mestroni L, Maisch B, McKenna WJ, et al. Guidelines for the study of familial dilated cardiomyopathies. *Eur Heart J* 1999; 20: 93-102.
93. Mangin L, Charron P, Tesson F, et al. Familial dilated cardiomyopathy: clinical features in French families. *Eur J Heart Fail* 1999; 1: 353-361.
94. Alroy J, Rush JE, Freeman L, et al. Inherited infantile dilated cardiomyopathy in dogs: genetic, clinical, biochemical, and morphologic findings. *Am J Med Genet* 2000; 95: 57-66.
95. Domanjko Petric A, Stabej P, Zemva A. Dilated cardiomyopathy in Doberman Pinschers: survival, causes of death and a pedigree review in a related line. *J Vet Cardiol* 2002; 4: 17-24.
96. Meurs KM. Familial dilated cardiomyopathy, *Advances in Canine and Feline Genomics. Comparative Genome Anatomy and Genetic Disease, St. Louis, Missouri, USA. 2002 (Abstract).*
97. Arbustini E, Morbini P, Pilotto A, et al. Genetics of idiopathic dilated cardiomyopathy. *Herz* 2000; 25: 156-160.
98. Bowles NE, Bowles KR, Towbin JA. The "final common pathway" hypothesis and inherited cardiovascular disease. The role of cytoskeletal proteins in dilated cardiomyopathy. *Herz* 2000; 25: 168-175.
99. Meurs KM, Magnon AL, Spier AW, et al. Evaluation of the cardiac actin gene in Doberman Pinschers with dilated cardiomyopathy. *Am J Vet Res* 2001; 62: 33-36.
100. Stabej P, Versteeg SA, Zijlstra C, et al. Candidate genes for dilated cardiomyopathy in dogs. *Proceedings of 11th ESVIM Congress* 2001: 98-99.
101. Dukes-McEwan J, Jackson IJ. The promises and problems of linkage analysis by using the current canine genome map. *Mamm Genome* 2002; 13: 667-672.
102. Fruscatti A, Chimenti C, Bellocchi F, et al. Histological substrate of atrial biopsies in patients with lone atrial fibrillation. *Circulation* 1997; 96: 1180-1184.
103. Rostagno C, Galanti G, Bertini G, et al. Doppler echocardiography in suspected lone atrial fibrillation. *Angiology* 1998; 49: 637-640.
104. Grogan M, Smith HC, Gersh BJ, Wood DL. Left ventricular dysfunction due to atrial fibrillation in patients initially believed to have idiopathic dilated cardiomyopathy. *Am J Cardiol* 1992; 69: 1570-1573.
105. Redfield MM, Kay GN, Jenkins LS, et al. Tachycardia-related cardiomyopathy: a common cause of ventricular dysfunction in patients with atrial fibrillation referred for atrioventricular ablation. *Mayo Clin Proc* 2000; 75: 790-795.
106. Azpitarte J, Baun O, Moreno E, et al. In patients with chronic atrial fibrillation and left ventricular systolic dysfunction, restoration of sinus rhythm confers substantial benefit. *Chest* 2001; 120: 132-138.
107. Bright JM. Treatment of atrial fibrillation: challenging the paradigm. *Proceedings of 20th ACVIM Forum* 2002: 103-105.
108. The Atrial Fibrillation Follow-Up Investigation of Rhythm Management (AFFIRM) Investigators. A comparison of rate control with rhythm control in patients with atrial fibrillation. *N Engl J Med* 2002; 347: 1825-1833.
109. van Gelder IC, Hagens VE, Bosker HA, et al. A comparison of rate control and rhythm control in patients with recurrent persistent atrial fibrillation. *N Engl J Med* 2002; 347: 1834-1840.
110. Tidholm A, Häggström J, Borgarelli M, Tarducci A. Canine idiopathic dilated cardiomyopathy. Part 1: Aetiology, clinical characteristics, epidemiology and pathology. *Vet J* 2001; 162: 92-107.
111. Olson TM, Michels VV, Thibodeau SN, et al. Actin mutations in dilated cardiomyopathy, a heritable form of heart failure. *Science* 1998; 280: 750-752.
112. McKenna CJ, Sugrue DD, Kwon HM, et al. Histopathological changes in asymptomatic relatives of patients with idiopathic dilated cardiomyopathy. *Am J Cardiol* 1999; 83: 281-283.
113. Mahon NG, Sharma S, Elliott PM, et al. Abnormal cardiopulmonary exercise variables in asymptomatic relatives of patients with dilated cardiomyopathy who have left ventricular enlargement. *Heart* 2000; 83: 511-517.